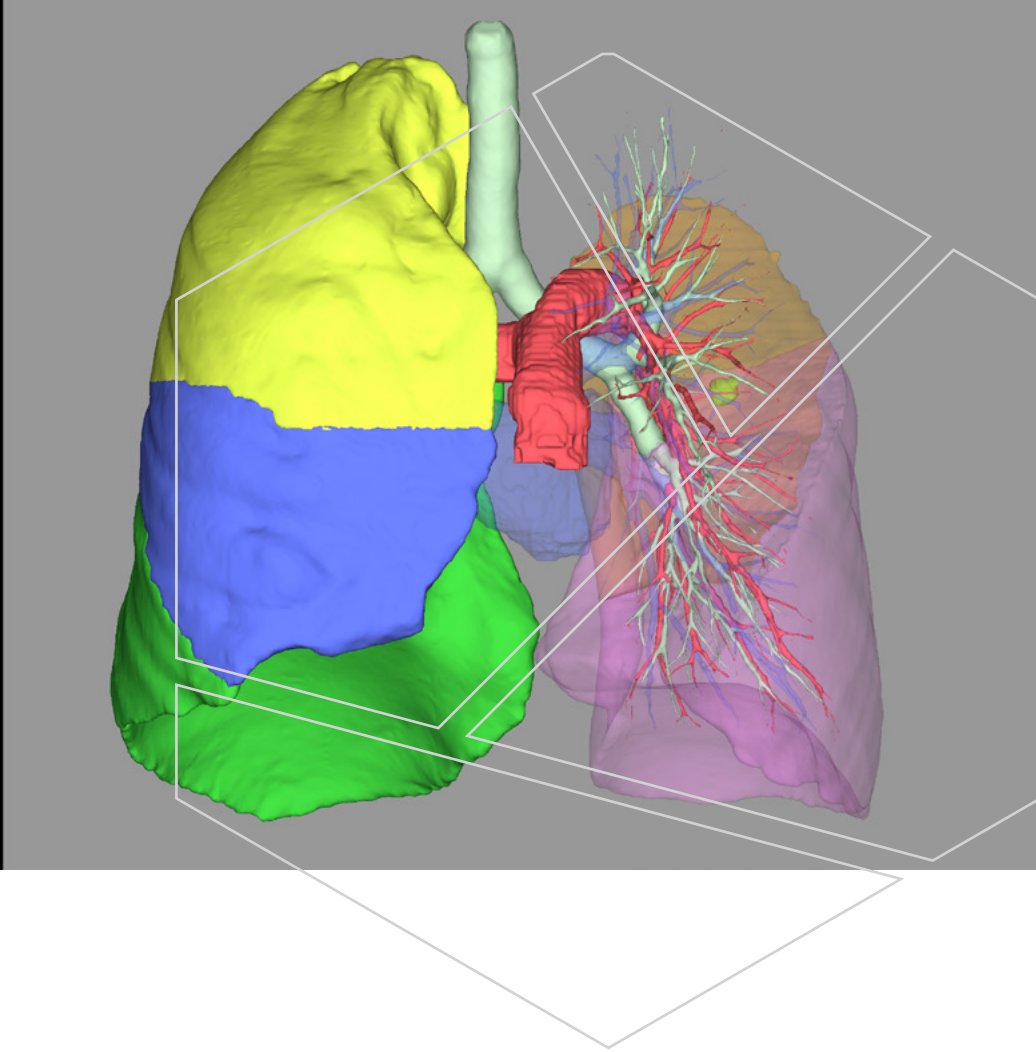
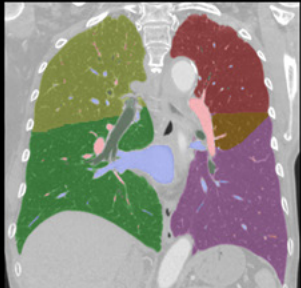
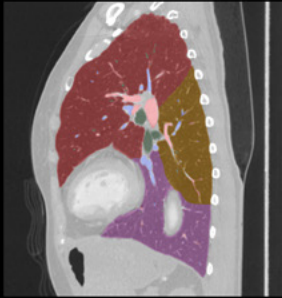
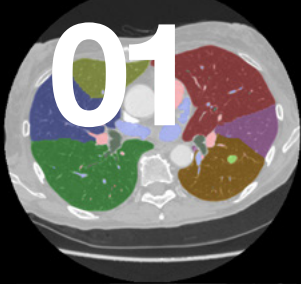


SYNAPSE 3D USER'S VOICE



Healthcare IT

How we use SYNAPSE 3D

Toyofumi Chen
M.D., Ph.D.

Department of Thoracic Surgery,
Kyoto University Hospital



Hiroshi Date,
Professor, M.D., Ph.D.

Department of Thoracic Surgery,
Kyoto University Hospital



SYNAPSE 3D is an image-assisted simulation software program that is useful for thoracic surgeons. Image-assisted simulation software is likely to be regarded as follows: “I have to ask a radiology technologist how to use the software,” or “I am not familiar with the usage of this kind of computer system.” However, we regard SYNAPSE 3D as a very user-friendly device that can be easily used by surgeons. Anyone can operate the device within 10 min because the actual use of the device is performed along the flow of the device’s operating system. The device is equipped with various options. Surgeons are likely to enjoy learning to use the device by themselves.

Below, we will introduce the actual use of the “Lung Analysis Scope” and “Lung Analysis Resection” options, which are part of the SYNAPSE 3D program, in a real-world setting, at our facility.

The “Lung Analysis Scope” option has the following two main uses:

1 Determination and simulation of lymph node puncture using endobronchial ultrasound-guided transbronchial needle aspiration (EBUS-TBNA)

EBUS-TBNA has emerged as a minimally invasive diagnostic technique in recent years. In many hospitals, it is used for assessment of tumors involving the mediastinal and hilar lymph nodes or of tumors that abut the trachea and bronchi prior to performing mediastinoscopy. EBUS-TBNA is a useful, minimally invasive modality. However, owing to the steep learning curve for this technique, its use in inexperienced facilities or for initial testing may not yield the expected results. This constraint can be overcome by three-dimensional reconstruction of the target lesion. At our facility, young surgeons often create virtual images using SYNAPSE 3D before proceeding to bronchoscope examination. Moreover, the device can be used for educational purposes.

2 Identifying the appropriate branch of the bronchi for the bronchoscopic procedure

In the following case of right upper lung cancer (Figure 1), surgical indication was determined after confirming negative N2. Although the lymph node (4R) (Figure 1A) was not enlarged on computed tomography (CT), we were not convinced that the lymph node was negative on positron emission tomography combined with computed tomography (PET/CT). Hence, EBUS-TBNA was performed (Figure 1B). The preoperative virtual bronchoscope image was very useful for grasping the relationship of the tracheal bifurcation and the target of biopsy (Figure 1C).

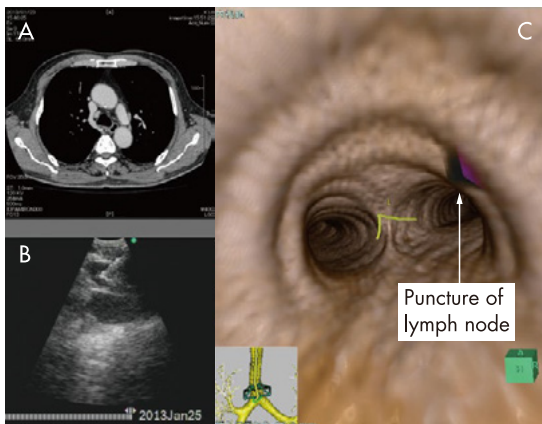
As for the case of left hilar lymphadenopathy after colorectal cancer surgery, we wanted to differentiate enlarged lymph nodes from multiple other lymph nodes. By virtual bronchoscope image, we were able to identify the actual target lymph node among several 11L lymph nodes (Figure 2).

Thus, SYNAPSE 3D allows us to perform EBUS-TBNA with a high degree of precision, even in inexperienced hands. The device delineates the target site in three-dimensional virtual images and helps to grasp the relationship of the biopsy target with anatomically contiguous structures.

It goes without saying that SYNAPSE 3D is useful for choosing the branches of the bronchi during diagnostic bronchoscopic procedures [such as transbronchial biopsy (TBB)].

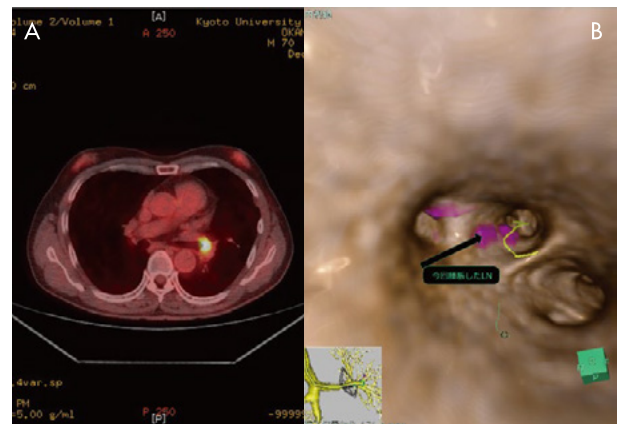
Furthermore, we use “Lung Analysis Scope” to identify the branches of the bronchi for performing preoperative bronchoscopic mapping in patients with micro lung cancer. Figure 3 of the tumor (blue arrow) in the segmental resection of the left S9 + S10 and the surrounding mapping (red arrow head) is shown. Furthermore, “Lung Analysis Resection” can extract the pulmonary artery and veins, as well as bronchi, and this feature enables us to recreate three-dimensional images of intrapulmonary blood vessels and bronchi based on commonly used contrast-enhanced CT data. Up to now, two-phase contrast-enhanced CT is required for providing clear contrast images of the pulmonary artery and veins; however, SYNAPSE 3D helps to create three-dimensional images with the use of commonly used one-phase contrast-enhanced CT. Therefore, this image-assisted simulation software will be more frequently used because the device is helpful for the immediate creation of three-dimensional images, even if contrast-enhanced CT imaging is performed in other hospitals. Currently, many young surgeons at our facility create simulated images of the cases under their care by themselves, as part of the workup for surgery.

◆ Figure 1



A 76-year-old male with right upper lobe lung cancer (cT2N0M0). EBUS-TBNA (B) was performed to confirm negative N2 before the surgery because PET/CT showed slight uptake in a mediastinal lymph node (4R) (A). Virtual bronchoscopy could clearly identify the target site for puncture of the lymph node (red).

◆ Figure 2



A 70-year-old male after surgery for colorectal cancer. Diagnostic EBUS-TBNA was performed due to enlargement of the left hilar lymph node and strong uptake on PET/CT (A). Virtual bronchoscopy could clearly identify the target site for puncture of the lymph node (red) from multiple lymph nodes.

3 Application in living-donor lung transplantation

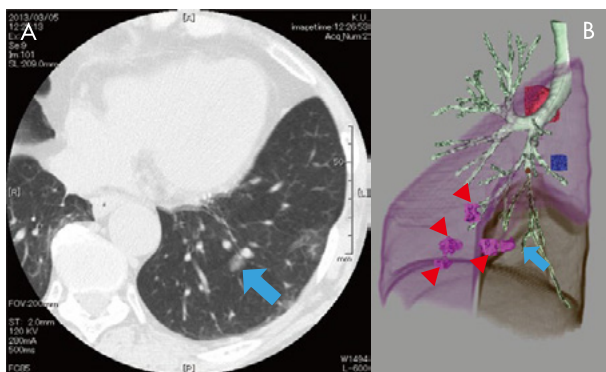
Here, we will introduce the actual use of the device in living-donor lung transplantation as one of the characteristic uses in our facility.

Figure 4 shows the lung volumes obtained on three-dimensional-CT volumetry in the right and left lower lobes of the donor's lung volume and in the right and left lung volumes of the recipient. These volumes are required for size matching between the donor's lung volume and the recipient's lung volume in living donor lung transplantation. In SYNAPSE 3D, each lung lobe volume is displayed automatically in this way (lower left corner of Figure 4). In addition, remaining lung function after pneumonectomy can be predicted easily because lung resection volume or residual lung volume after segmentectomy or subsegmentectomy can be displayed automatically and instantaneously (feature not displayed here).

Furthermore, the branch pattern of vessels and bronchi in the right lower lobe of the donor is shown in Figure 5. Although Figure 5A is a basic Volume Rendering (VR) display, the display can change to Surface display (Figure 5B). The resection line for the interlobar part of the pulmonary artery is shown as a white dotted line, which is part of the standard procedure for preparation of the donor for surgery.

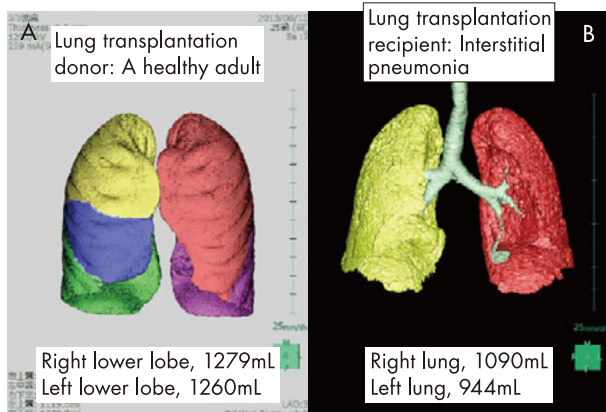
In the case of the left lower lobe, the resection line of the pulmonary artery is often an apparently inclined line because of the position between V4, V5, and the location of the A6 bifurcation. In such cases, pulmonary arterioplasty with a auto pericardial patch is often required. Therefore, a detailed preoperative plan and preparation are important for the safety of both the donor and the recipient.

◆ Figure 3



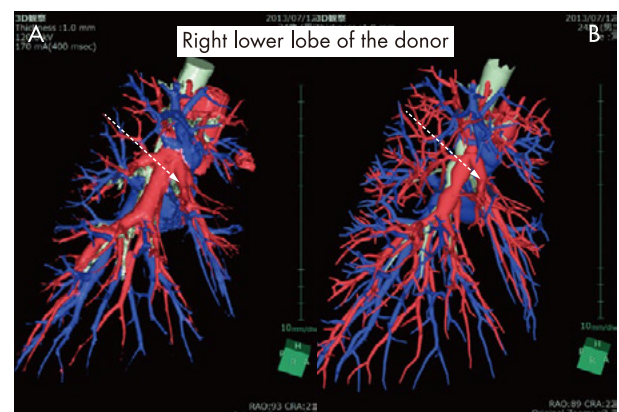
Preoperative bronchoscopic lung mapping for micro lung cancer. CT showed a lesion (a few millimeters) with ground-glass opacity (GGO) in the S9 region (A). An image of virtual dyed mapping (B); the mapping image was confirmed on a second CT scan after transbronchial dyed mapping. The tumor (blue arrow) and surrounding mapping (red arrow head) are clearly shown.

◆ Figure 4



3D-CT lung lobe volumetry of the donor and recipient in living donor lung transplantation

◆ Figure 5

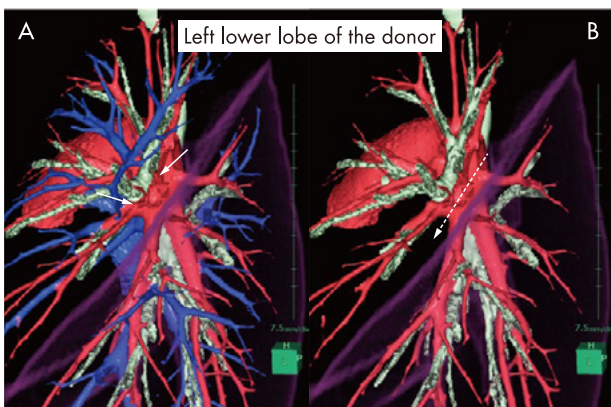


3D images of the vessels and bronchi in the right lower lobe of the donor's lung

An example is shown in Figure 6. In Figure 6A (preoperative), it is expected that two small pulmonary branches (white arrow) must be treated when we consider the resection line of the interlobar part of the pulmonary artery. The display can change only the pulmonary arteries to hide pulmonary veins (Figure 6B) by one click and the white dotted line shown represents the resection line for the pulmonary artery. In addition, it is also possible to display only the bronchi by hiding vessels (Figure 7A). In addition, the three-dimensional images enable anatomy confirmation of pulmonary vein branches. In this case, prior to surgery, a white dotted line or the resection line helped to confirm the safety of surgery in the donor (Figure 7B).

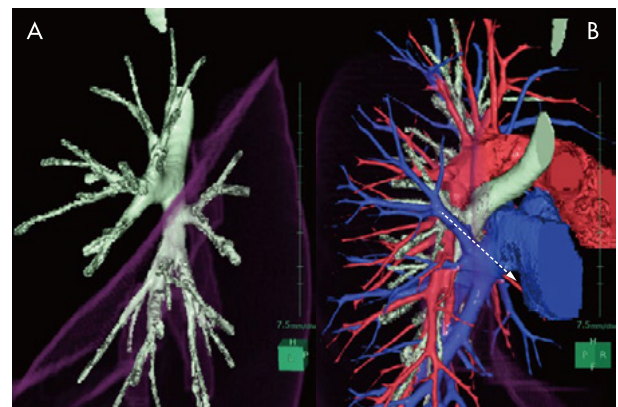
In this case, in accordance with the preoperative plan, the donor's left lower lobe was resected as a white dotted line on the pulmonary artery (Figure 6B) using a auto perocardial patch. The recipient's lung was anastomosed by leaving the self-pulmonary artery diagonal construction. Hence, living- donor lung transplantation was performed without any complications. SYNAPSE 3D facilitated perioperative operation, and it became a key to successful accomplishment of the surgery as per the plan.

◆ Figure 6



3D images of the vessels and bronchi in the left lower lobe of the donor

◆ Figure 7



3D images of the vessels and bronchi in the left lower lobe of the donor